

Sample Narratives for Insurance Billing

Crowns: Please note initial placement date if possible plus any risk factors that contribute to breakdown.

- Crown present when patient became active in our office; patient states that crown is over 10 years old.
- Recurrent decay ML and DB of existing MOD amalgam #31; Filling occupies 2/3 of tooth structure-initial placement of crown - see attached I/O image.
- Distolingual margin open on existing crown #3; recurrent decay present upon removal of existing crown.
- existing MOD #4 amalgam that covers 3/4 of buccal lingual occlusal surface. Mesial and distal areas extend into buccal and lingual surfaces also - filling is cracked across mid-occlusal.
- Patients presents with pain on biting #14-sensitive to hot and cold also. Fracture line that extends from occlusal surface to MB line angle. Used tooth sleuth for evaluartion- pain indicated on MB cusp. Crown recommended for cracked tooth.

Buildups:

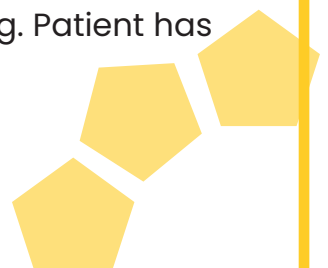
- More than 1/2 of the tooth structure is missing after removal of existing filling material and decay.
- Less than 2 - 3mm collar of sound totth structure remaining around gingival margin-build up necessary for retention of crown.

Fillings with multiple surfaced- not connected:

- Buccal pit placed and occlusal filling placed. They are seperate fillings, not connected. Please reimburse as stated.
- Fillings placed in distal occlusal pit DO and in mesial occlusal pit MO. Fillings did not connect. Please reimburse as two seperate fillings.
- Fillings placed in mesial occlusal pit and distal occlusal pit that connects to the lingual surface- the two fillings MO and OL did not connect- please reimburse as two seperate fillings.

Occlusal Guards: List Risk Factors that are present (Bite and Function, TMJ):

- Patient exhibits signs of bruxism from grinding at night. Complains of jaw pain upon waking.
- General attrition of tooth structure due to clenching and grinding. Patient has pain with biting and severe jaw pain after sleeping.





Implant placement followed by temporary bridge or flipper:

- Extraction date 2/12 while on this plan; prosthetic will maintain space during implant site healing.
- Extraction completed on 10/15/13 and implant placed same day. Removable prosthetic to maintain space during healing.

Payment requested of periodontal maintenance after treatment: List risk factor: genetics, smoking, diabetes, medications, inflammatory diseases

- Scaling and root planning performed on patient in June 2010 while covered under this plan: periodontal risks of Inflammatory Crohns Disease and medications. AAP: Type II-severe chronic generalized.
- Scaling and root planing completed May 2012 at previous dental office under another dental plan. Patient has diabetes and HBP meds that causes dry mouth. AAP: Type II Chronic Moderate Generalized.
- Please apply benefits for D1110 if no benefit exists for D4910.

Pulp caps:

- Teeth #Band S had deep visible caries and caries evident on radiographs. After the caries was removed, the decay was very deep in both teeth. Since the fillings were very close to the nerve, pulp caps were necessary to protect against possible irritation of the pulp chambers. Pulp caps were placed to protect the teeth from further trauma. The teeth have been asymptomatic since placement. Please reimburse as coded on the attached claim.

Temporary Partial used as permanent-per patient choice:

- Please reconsider John Day's March 1, 2013 claim for a lower partial denture. This prosthetic falls outside your missing tooth clause since tooth #20 was extracted on Sept. 7, 2010 while covered under this plan. The reason for denial on the EOB is that this prosthetic is considered a temporary prosthetic. This however is not the case. Mr. Day realizes that the prosthetic. Mr. Day requested the all resin partial and understood that this was to be a permanent prosthetic. He was also made aware of the replacement clause within his dental contract.



Bone Grafting after extraction:

- Tooth #18 was extracted on 5/6/13. I determined the tooth not salvageable due to infection and a vertical fracture onto the root structure on the mesial. After discussing this with the patient, it was agreed to extract the tooth and have bone grafting material placed within the socket to preserve the bone. Bone grafting was needed the same day to enhance healing. To place the material on a different day would have necessitated a re-opening of the socket that would have destroyed any healing that had occurred.

Crown Lengthening:

- Crown lengthening needed on tooth #28 due to improper biological width. Without the procedure the crown margin would have been placed too close to the bone.

Removable Prosthetics:

- Prosthetic needed to replace missing teeth 9, 10, 11, 14, 1. Teeth have been missing for over 6 years according to patient—extracted due to deep decay and pain.
- Prosthetic will replace missing teeth #3-5, 12-14. Teeth extracted over 10 years ago according to patient.

Alternate Bridge or Removable Benefit for Implant:

- Short version: Pt. is aware that policy does not cover implants. Please apply alternate benefit clause for removable prosthetic. (back teeth missing)
- Long version: The patient is aware that the policy does not cover implant placement or restoration. Please consider benefits for the alternate treatment of a 3 unit bridge or removable prosthetics. The patient is aware that the replacement clause limitation will be applied. Please call with any questions.
- For Implant claims, include date of extraction and if it was covered under this plan, note that also. If unknown, get the patient's closest estimate.

Anterior Veneers:

- Teeth #6 through #11 had full facial incisal composites with leaking margins and recurrent decay present. #10 had a MIF composite with open margins and recurrent decay. Vertical fractures from incisal edge to gingiva were present on the mesial and distal surfaces of #7, #8 and horizontal fracture from mesial to distal on facial of #9, #10.





Periodontal Procedures:

- Patient presents with clinical attachments loss of 4–7 mm generalized throughout the mouth. Active infection indicated with generalized bleeding upon probing. Risk factors include smoking, diabetes and medications that cause dry mouth. AAP Type II advanced localized and moderate generalized infection.
- Radiographs and periodontal readings attached (send complete probing with mobility, furcation, missing teeth, recession and bleeding noted. Send full-set radiographs of up to 3 years but also send most current bitewing set – preferably 4 bw's).

